

Slicer

Observing MPR / CPR Slice Image of Spine

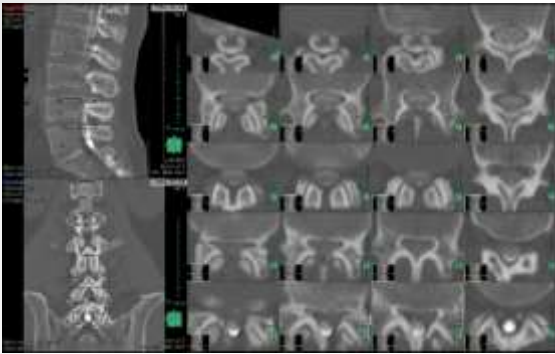
Recommended Image ▶ CT

Analysis image conditions ▶ Spine and Extremities

Automatic spine detection for MPR slice image and observe CPR image tracking the detected line

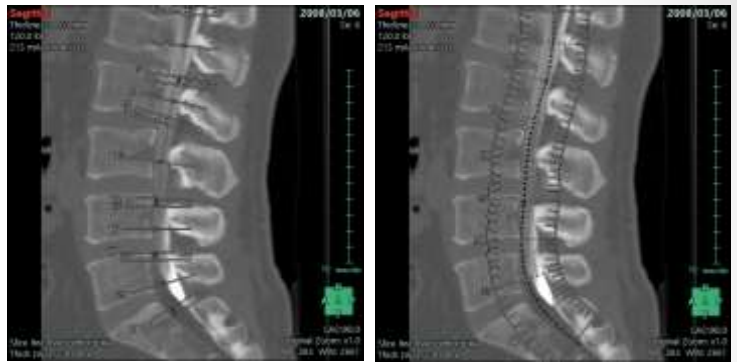
Spinal Cord Detection

Total Spine View



Automatically detect spinal cord

Slice Type

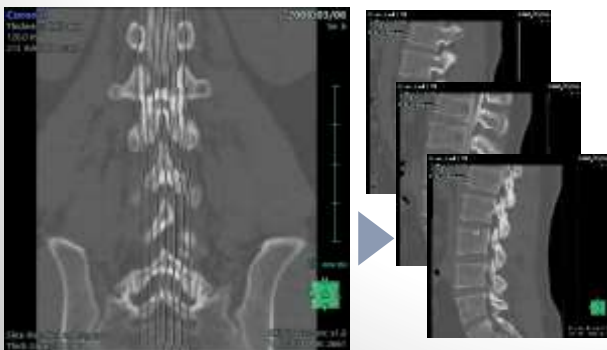

Single Slice & Slice Box

Line Slice type

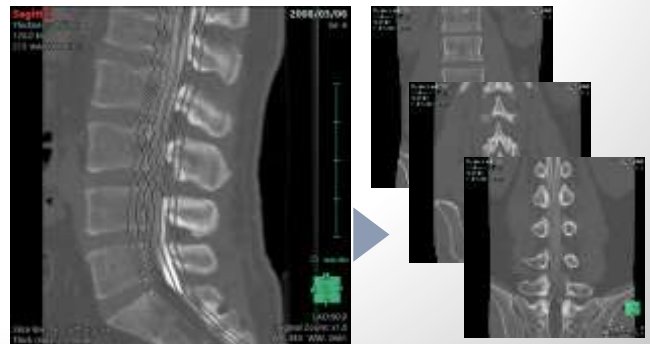
CPR View

CPR 1 Sagittal



Automatic Sagittal CPR image from detected Spinal

CPR 2 Coronal



Automatic Coronal CPR image from detected Spinal